Check for updates

Received: 2 March 2023 | Revised: 2 June 2023 | Accepted: 9 August 2023

DOI: 10.1111/sms.14472

ORIGINAL ARTICLE

WILEY

Chronic changes in muscle architecture and aponeurosis structure following calf muscle strain injuries

Louise B. Nielsen[1,2] | Rene B. Svensson[1,2] | Niels U. Fredskild[1,2] | Kenneth H. Mertz[1,2] | S. Peter Magnusson[1,2,3] | Michael Kjaer[1,2] | Monika L. Bayer[1,2]

[1]Institute of Sports Medicine Copenhagen, Department of Orthopedic Surgery M, Copenhagen University Hospital – Bispebjerg Frederiksberg, Copenhagen, Denmark

[2]Center for Healthy Aging, Faculty of Health and Medical Sciences, University of Copenhagen, Copenhagen, Denmark

[3]Department of Physical Therapy, Copenhagen University Hospital – Bispebjerg Frederiksberg, Copenhagen, Denmark

Correspondence
Monika L. Bayer, Department of Orthopedic Surgery, Institute of Sports Medicine Copenhagen, Copenhagen University Hospital – Bispebjerg Frederiksberg, Nielsine Nielsens Vej 11, Copenhagen NV 2400, Denmark.
Email: Monika.lucia.bayer@regionh.dk

Funding information
Bispebjerg Hospital; Kulturministeriet

Abstract

Background: Muscle strain injuries in the human calf muscles are frequent sports injuries with high recurrence. Potential structural and functional changes in the medial head of the musculus gastrocnemius (GM) and the associated aponeurosis are not well documented.

Purpose: To test whether a GM muscle strain injury affects muscle fascicle length, pennation angle, and the morphology of the deep aponeurosis at rest and during muscle contraction long time after the injury. Additionally, electromyography (EMG) of the GM and the soleus muscle during a unilateral heel rise was measured in the injured and uninjured calf.

Methods: GM fascicle length, pennation angle, and aponeurosis thickness was analyzed on dynamic ultrasonography (US) recordings in 10 participants with a chronic calf strain. In addition, US images taken across the distal portion and mid-belly of the GM were analyzed at three different ankle positions. EMG recordings were obtained during a unilateral heel rise.

Results: The pennation angle of the injured distal GM was significantly larger compared to the uninjured GM in the contracted, but not the relaxed state. Pennation angle increased more in the injured compared to the uninjured GM during contraction. Fascicle length was shorter in the most distal portion of the injured GM. Fascicles at the distal portion of the injured GM showed a pronounced curvilinear shape as the muscle contracted and the aponeurosis was enlarged in the injured compared to the uninjured GM. The ratio between GM and soleus EMG activity showed a significantly higher relative soleus activity in the injured compared to the healthy calf.

Conclusion: The greater change in pennation angle and curvilinear fascicle shape during contraction suggest that a long-term consequence after a muscle strain injury is that some muscle fibers at the distal GM are not actively engaged. The significantly enlarged aponeurosis indicates a substantial and long-lasting connective tissue involvement following strain injuries.

This is an open access article under the terms of the Creative Commons Attribution-NonCommercial License, which permits use, distribution and reproduction in any medium, provided the original work is properly cited and is not used for commercial purposes.
© 2023 The Authors. *Scandinavian Journal of Medicine & Science In Sports* published by John Wiley & Sons Ltd.

KEYWORDS
calf strain, connective tissue, dynamic ultrasound imaging, muscle injuries

1 | INTRODUCTION

Muscle strain injuries in the human hamstrings or calf muscles are one of the most common sports injuries in both competitive and amateur athletes, and are associated with a high reinjury rate.[1–3] Calf muscle strain injuries are frequent in sports involving highspeed running and sudden acceleration.[3,4] Previous studies have shown that muscle strain injuries almost exclusively occur at the interface between the muscle and tendon (aponeurosis).[5–9] As the insertion of muscle fibers into the aponeurosis is affected, reestablishing a firm and functional attachment between the muscle fibers and the connective tissue after a strain injury is necessary to restore optimal function. This means that the interface is resistant to high muscular forces and able to efficient transmit muscular force to the aponeurosis, tendon, and then bone. However, previous studies have documented that strain injuries often cause long-standing muscle atrophy,[8–10] fibrosis, and fatty infiltration in both the hamstring and calf muscles,[10] which suggest that the repair process is incomplete.

Structural changes of injured human skeletal muscle and the aponeurosis have been sparsely investigated. The aponeurosis is a sheet-like tendinous structure that covers a portion of the muscle belly and serves as the insertion site of muscle fibers.[11–14] Importantly, the loading pattern of aponeuroses is complex as aponeuroses can undergo positive strains in more than one direction. Aponeuroses can undergo stretch in the longitudinal direction and in directions orthogonal to the muscle's line of action.[11,12] Further, it has been shown that the aponeurosis at different portions of the muscle behaves differently. While the soleus mid-belly aponeurosis showed positive strain during a submaximal contraction, negative strain of the distal aponeurosis was reported,[15] adding to the complexity of the aponeuroses' mechanical properties. Whether these distinct mechanical properties of the aponeurosis are altered following a strain injury is unknown.

In the hamstring muscles, a short length of the fascicles in the biceps femoris long head (BFlh) has recently been identified as a risk factor for hamstring strain injury.[16] Further, eccentric exercises such as the Nordic Hamstrings have repeatedly been shown to have a significant preventive effect on hamstring strain injuries[17,18] and eccentric exercises have been shown to increase fascicle length.[19] These findings suggest that at least part of the protective effect of eccentric exercises are a result of the increase in fascicle length. Interestingly, a recent study on hamstring muscle strains and the effect of rehabilitation with early onset of eccentric exercises showed that there was a greater increase in fascicle length in the injured compared to the healthy non-injured hamstring muscles.[20] It is also interesting to note that in this study, the participants with the longest return to sport (RTS), and presumably the greatest damage, had no increase in fascicle length during the rehabilitation period. There might be an association between the severity of the injury, the associated structures, such as the aponeurosis and adaptations, or the lack of these in response to rehabilitation/heavy loading of the muscle-tendon unit. It has remained unknown how fascicles and associated structures behave a long time after the injury. Further, while there is substantial research performed on hamstring strain injuries, both in the preventive and rehabilitative state, the gastrocnemius strain injuries have received very little attention, despite their high prevalence (e.g., 6% per season in professional male soccer).[21]

On a technical note, studies on fascicle length in the hamstring muscles suffer from the challenge that fascicles cannot be tracked from the superficial to the deep aponeurosis. The dimensions of the ultrasound (US) probe length result in a visible portion of the fascicle length that corresponds to ~50%[22] and length has to be calculated using linear extrapolation methods, which do not take fascicle and aponeurosis curvature into account.[22] Importantly, a recent US study reported systematic errors, which appear to differ between participants, complicating the interpretation of studies on fascicle length.[22] A clear advantage in studying the gastrocnemius medialis (GM) is that fascicles can largely be traced from their origin to the insertion, and therefore, systematic errors due to extrapolation methods are markedly reduced.

In addition to structural changes, it is possible that neuromuscular changes take place after a strain injury. In fact, a reduction in the surface EMG activity of the BFlh during eccentric contractions has been reported following strain injuries,[23–25] and the muscle activation pattern may be chronically changed following a strain injury.[25] Whether the muscle activation pattern following calf muscle strains is altered has not been investigated.

In this study, we investigated the effect of a previous GM muscle strain injury on muscle fascicles, pennation angle and the morphology of the deep aponeurosis at rest and during muscle contraction. In addition, electromyography of the GM and the soleus muscle during unilateral heel rise movements were compared to the contralateral

16000838, 0, Downloaded from https://onlinelibrary.wiley.com/doi/10.1111/sms.14472 by Ohio State University Ohio Sta, Wiley Online Library on [25/08/2023]. See the Terms and Conditions (https://onlinelibrary.wiley.com/terms-and-conditions) on Wiley Online Library for rules of use; OA articles are governed by the applicable Creative Commons License

uninjured side. We hypothesized that fascicle length is shorter in the injured compared to the healthy GM and the pennation angle steeper. We further hypothesized that the EMG activity of the GM is reduced in the injured compared to the healthy calf during the heel rise movement.

2 | MATERIALS AND METHODS

2.1 | Study design and participants

This study was an observational cross-sectional study including 11 participants. One male participant, however, had to be excluded due to a previously undiagnosed condition in the healthy calf presenting as severe muscle weakness (unable to perform a single unilateral heel rise). The number of participants involved in this study is therefore $n=10$ (3 female, 7 male). All participants were recruited from a previous[26] or an ongoing study on muscle strain injuries at the Institute of Sports Medicine Copenhagen, and were enrolled in this study between May 2020 and June 2021. Please see Table S1 for participant characteristics including type of sports and the exact duration since injury. The most common symptom reported by the participants was weakness of the affected side. All participants were non-smokers and free from any chronic disease affecting the musculoskeletal system. Both studies were approved by the local ethical committee (reference H-1-2014-005 and H- 19027293).

2.2 | Ultrasound imaging

Ultrasound (US) images were recorded in B mode using a HITACHI HI VISION Ascendus ultrasonography device with a 10 cm, 9 MHz linear probe. Still images were recorded in three different ankle joint positions while participants were lying prone: (1) neutral ankle joint (~110°), (2) ankle joint in 90°, and (3) ankle joint in 80° position (dorsiflexed). In all ankle joint positions, images were taken at the distal part of the GM muscle, covering the muscle-tendon junction central (1), medial (2), and lateral (3). Thereafter, US images were recorded in the mid-belly GM in the central (4), medial (5), and lateral (6) (Figure 1A,B).

Following the still images, dynamic US recordings were made as the participants performed unilateral heel rises.

2.3 | Ultrasound recordings during unilateral heel rise task

For the heel rise movement, the MuscleLab (Ergotest Technology) system was used, which consists of a string

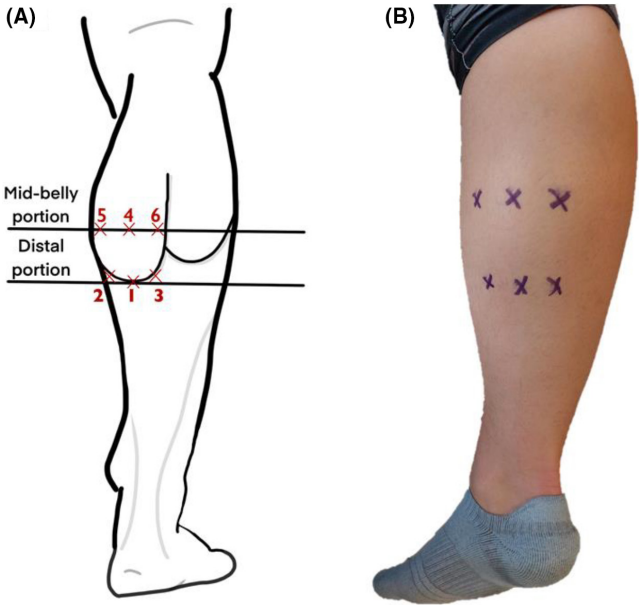

FIGURE 1 Overview of the ultrasound probe positions at different sites of the calf. (A) markers on a schematic illustration, (B) markers placed on skin. The probe positions marked as crosses on the skin are the following: Distal portion: (1) central, (2) medial, and (3) lateral. Mid-belly portion: (4) central, (5) medial, and (6) lateral.

connected to a sensor inside a linear encoder unit, which outputs the distance traveled.[27] For balance, the participants were instructed to place two fingertips per hand against a wall at shoulder height. The knee joint was maintained in complete extension during the entire movement (knee position 0°). If the knee position was not straight, the trial was discarded. The participants were instructed to slowly rise on each heel-rise and then lower the heel to the starting position with concentric and eccentric phases each lasting 3 s guided by audio feedback. The range of motion was fixed to approximately 6 cm of heel rise from the ground, with further movement limited by a string attached to the calcaneus. The actual distance of each heel rise movement was recorded and only heel rises deviating less than 0.5 cm (±) were included in the analysis. Limited range of movement was chosen to allow comparison at approximately the same distance in the injured and the healthy calf. Videos were recorded on GM, primarily at both the distal end covering the central region of the muscle-tendon junction and in six participants, it was also recorded more proximally in the central region of the muscle mid-belly (Figure 1).

2.4 | Ultrasound image/Video analysis

To analyze pennation angle and fascicle length, an automated approach was adopted to reduce evaluator

16000838, 0, Downloaded from https://onlinelibrary.wiley.com/doi/10.1111/sms.14472 by Ohio State University Ohio Sta, Wiley Online Library on [25/08/2023]. See the Terms and Conditions (https://onlinelibrary.wiley.com/terms-and-conditions) on Wiley Online Library for rules of use; OA articles are governed by the applicable Creative Commons License

influence. Using FIJI/ImageJ (v.1.52n, National Institute of Health, USA), a macro was developed to determine the so-called structure tensor, which can be used to determine gradient directions. The structure tensor was determined in every pixel, using the intensity gradients in a 1-pixel radius and performing a weighted integration by a Gaussian distribution with a radius (standard deviation) of four pixels. The structure tensor was then solved for the eigenvectors to determine the local orientation vector in each pixel. To restrict the analysis to well-defined muscle fascicles, a threshold was applied to isolate the brightest image regions, followed by a "skeletonize" function to extract the central "backbone" of these regions. Branches in the skeleton were separated and only branches longer than 40 pixels (4.1 mm) were included. The selected structures were then manually curated to remove those that did not correspond to a muscle fascicle. The angle of the fascicle was then determined as the vector average of the eigenvectors in each pixel of the fascicle "backbone." In addition, the superficial and deep aponeuroses were manually outlined, and the selected muscle fascicles were extrapolated to their intersection point with each aponeurosis to determine the pennation angle at the intersection (Figure S1). Only fascicles that intersected both aponeuroses were included in the analysis and the straight linear distance between the intersection points was taken to be the fascicle length. For each image, the peak pennation angle and the associated fascicle length was determined. The reason for using the peak rather than average value is that the algorithm tends to underestimate the pennation angle (determined by visual inspection) due to some more horizontal structures being present (blood vessels).

Ultrasound videos during heel rise were also analyzed using FIJI. A number of points (Figure 2A distal and 2B mid-belly) were manually designated on the first frame of the video prior to raising the heel ("relaxed"), then the motion of those points was manually traced through the video and marked at the frame with peak contraction. The points define the most distal fascicle (F1 for distal scans, F3 for mid-belly), the least distal fascicle that remains within the field of view throughout the contraction (F2 for distal scans, F4 for mid-belly). The aponeurosis thickness was measured at the insertions of these fascicles (D1 at the F1 insertion, D3 at the F2 insertion, M1 at the F3 insertion, and M3 at the F4 insertion, see Figure 2) and at the thickest point of the aponeurosis defined by manual inspection (D2 and M2). From these points the straight fascicle length, pennation angle, and aponeurosis thickness in the precontracted and maximally contracted state was determined. To determine the deep pennation angle, the angles of the aponeuroses were defined as the angle between the insertion points of the two fascicles (points 1 and 4 in Figure 2). The pennation angle was calculated as the angle between the deep aponeurosis and the fascicle

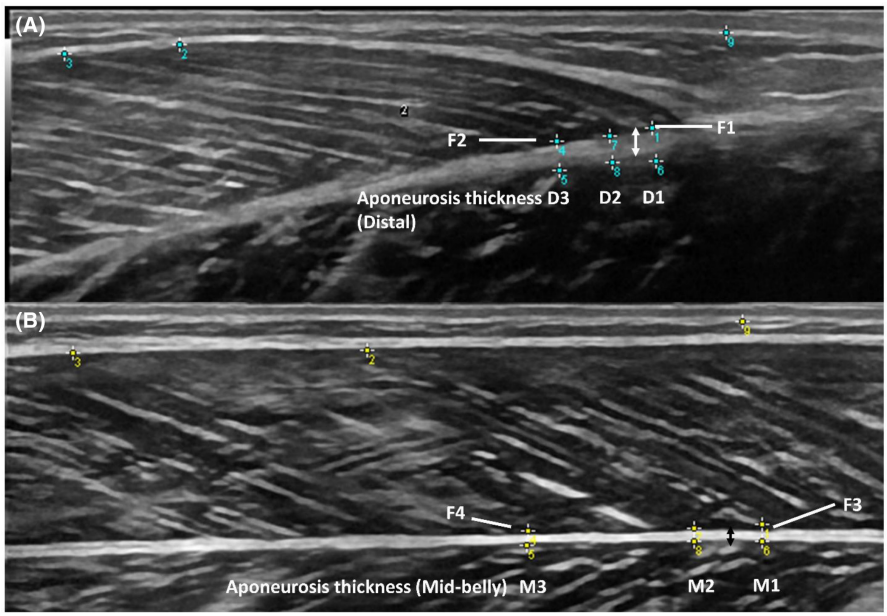

FIGURE 2 Ultrasound images illustrating the video analysis of the GM during a heel rise. Uninjured distal (A) and uninjured mid-belly (B) GM at peak contraction. Markers indicate the following: 1: Most distal fascicle F1 deep aponeurosis insertion (distal)/F3 insertion (mid-belly), 2: Most distal fascicle F1 superficial aponeurosis origin (distal)/F3 origin (mid-belly), 3: Distal fascicle F2 superficial aponeurosis origin (distal)/F4 origin (mid-belly), 4: Distal fascicle F2 deep aponeurosis insertion (distal)/F4 insertion (mid-belly), 5: Aponeurosis thickness at fascicle F2 insertion "D3" (distal)/F4 insertion "M3" (mid-belly), 6: Aponeurosis thickness at fascicle F1 insertion "D1" (distal)/F4 insertion "M1" (mid-belly), 7/8: Aponeurosis thickness at the most enlarged point, "D2" (distal)/"M2" (mid-belly) 9: Fix-point on skin to control for US probe movement during contraction.

16000838, 0, Downloaded from https://onlinelibrary.wiley.com/doi/10.1111/sms.14472 by Ohio State University Ohio Sta, Wiley Online Library on [25/08/2023]. See the Terms and Conditions (https://onlinelibrary.wiley.com/terms-and-conditions) on Wiley Online Library for rules of use; OA articles are governed by the applicable Creative Commons License

line between the origin and insertion points (e.g., points 1 and 2 in Figure 2).

2.5 | Electromyography

Bipolar electromyographic (EMG) recordings were obtained by placing surface electrodes (Ag/AgCl Blue-Sensor N-00-S, AMBU, Ballerup, Denmark) over the skin of the medial GM and distal soleus muscles on the healthy and the injured leg with an interelectrode distance of 2 cm. A reference electrode was placed on the tibial bone. Before electrode attachment, the skin was shaved, abraded, and prepared with an alcohol wipe. The EMG signals were recorded wirelessly at a sampling frequency of 1500 Hz using 16 bit analogue-to-digital resolution (Telemyo 2400T G2 Telemetry system, Noraxon USA Inc). EMG was recorded during maximal voluntary contraction (MVC) for the plantar flexors while seated with a knee angle of 0° (extended knee) and thereafter, EMG was measured during three unilateral heel rises following 2–3 familiarization trials. The participants were instructed to slowly raise their heel as high as possible over 3 s and lower the heel back to the starting position over 3 s. Note that the movement was not separated into the concentric and the eccentric compartment. The EMG recordings were exported from Noraxon to Matlab for further processing to convert the raw signals to linear envelopes by full-wave rectification and digitally low-pass filtering (Butterworth third-order filter, cut-off frequency: 1 Hz). The peak value of the filtered EMG signal in each trial was determined and averaged over at least three repeated trials. Note that for the heel rise task, this is the maximal activity across both the concentric and eccentric phases, which in most recordings occurred near the point of maximum heel rise. The EMG activity during heel rise of the soleus and GM respectively were normalized to their activity in the MVC at 0° knee flexion.

2.6 | Statistics

The differences of pennation angle, fascicle length, and aponeurosis thickness from US still images and US video recordings between the injured and the uninjured GM were analyzed by repeated measures two-way mixed model using the GraphPad Prism 9.0 software. For video recordings, the factors were side (injured vs. uninjured GM) and contraction state (relaxed vs. contracted). For US still images, the factors were side and ankle angle (110°, 90°, and 80°). In case of interactions, multiple comparisons were analyzed with the Šídák correction. Interactions and main effects are presented as differences between means, p-values and the 95% confidence intervals (CI). The differences of normalized EMG signals during heel rise tests between the legs were tested by paired t-tests. Data on figures are represented as difference of means, p-value and ±95% CI and the level of significance was set at $p < 0.05$.

3 | RESULTS

3.1 | Participants

This study included 10 participants (3 female, 7 male), 45.3 (±8) years on average, with a mean BMI of 24.8 (±1.6). All participants had a previous chronic calf muscle strain injury with a mean duration of 47 ± 25 months from injury onset until US investigation in the present study. Please see Table S1 for participant characteristics including type of sports and the exact duration since injury. Due to technical reasons, dynamic US recordings of the mid-belly GM were performed on six participants while all the other measurements were performed on all participants (see Table S1 for details).

3.2 | Pennation angle

The analysis of the US images taken in three different ankle positions revealed no statistical interactions. For all scan locations on the distal GM there were significant main effects of the ankle angle. At the central position, the pennation angle at 110° was larger compared to the 90° (5.1°, $p = 0.02$, CI = 0.8–9.4°), and 80° (5.8°, $p = 0.006$, CI = 1.5–10.0°), (Figure 3A). Similarly, for the medial position the pennation angle at 110° was higher than at 90° (3.7°, $p = 0.02$, CI = 0.5–7.0°) and at 80° (6.9°, $p < 0.0001$, CI = 3.6–10.2°), (Figure 3B). At the lateral position, the pennation was only significantly greater at the 110° position compared to the 80° position (3.7°, $p = 0.02$, CI = 0.5–6.9°), (Figure 3C). There was no statistical difference in pennation angle between the injured and the uninured side for any of the distal scan locations. These data fit the observation of the video analysis presented below where the pennation angle in the relaxed state was similar between the injured and the uninjured GM (Figure 4A,B). Pennation angle at mid-belly showed a main effect of ankle angle at the medial and lateral but not the central position. At the medial position, pennation angle was steeper at 110° compared to 90° (5.4°, $p = 0.0005$, CI = 2.5–8.4°) and 80° (8.5°, $p < 0.0001$, CI = 5.6–11.4°), and pennation angle was also greater at 90° compared to 80° (3.1°, $p = 0.04$, CI = 0.1–6.0°), (Figure 3D). At the lateral position, pennation angle was higher at 110° compared to both 90° and 80° (4.8°, $p = 0.0001$, CI = 2.5–7.2° for both

16000838, 0, Downloaded from https://onlinelibrary.wiley.com/doi/10.1111/sms.14472 by Ohio State University Ohio Sta, Wiley Online Library on [25/08/2023]. See the Terms and Conditions (https://onlinelibrary.wiley.com/terms-and-conditions) on Wiley Online Library for rules of use; OA articles are governed by the applicable Creative Commons License

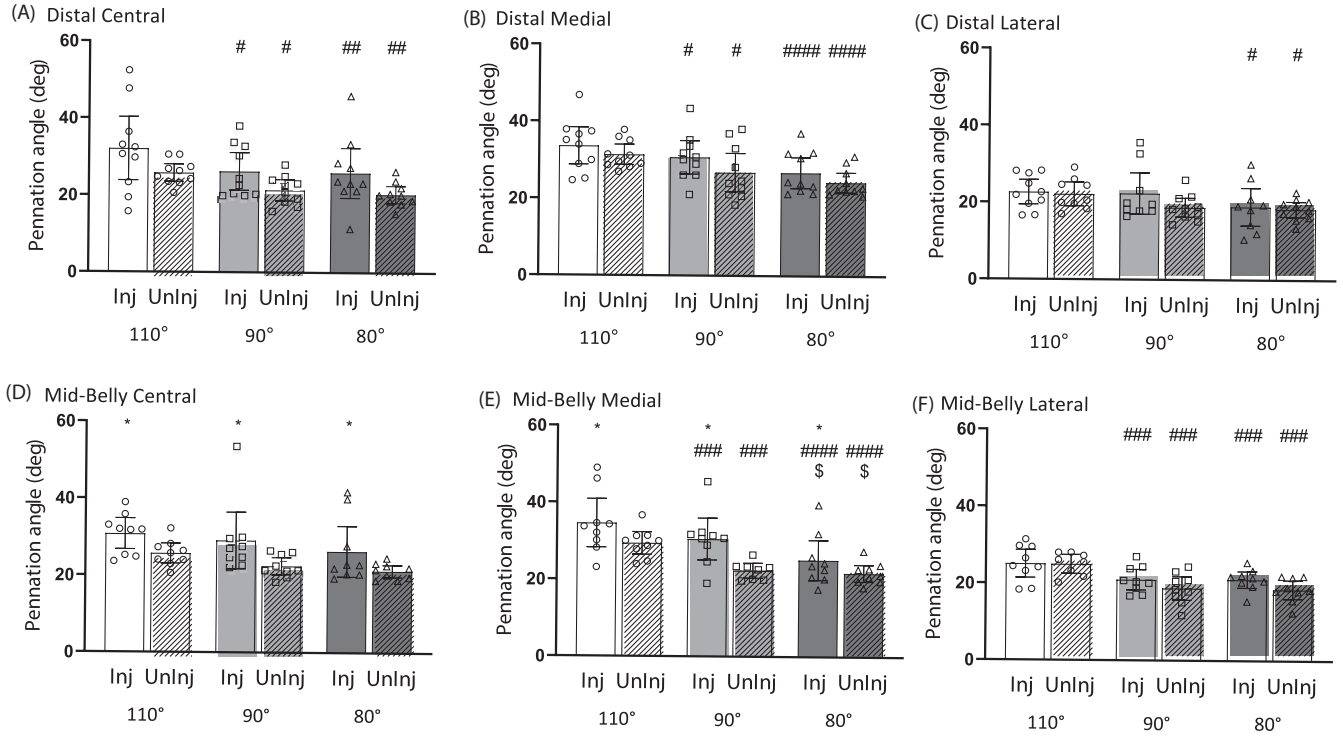

FIGURE 3 Pennation angle at the distal (A–C) and mid-belly (D–F) region of the GM at the three different ankle positions measured on ultrasound images. (A) and (D) central portion of the GM, (B) and (E) medial portion of the GM and (C) and (F) lateral portion of the GM. White bars = ~110°, light gray bars = ~90° and dark gray bars = ~80°. $N = 10$. Inj, injured; UnInj, Uninjured (striated bars). *Significant difference from uninjured; #, significant difference from 110°; $, significant difference from 90°. Main effects reported. Mean ± 95% CI $^{\#}p < 0.05$, $^{\#\#}p < 0.01$, $^{\#\#\#}p < 0.001$, $^{\#\#\#\#}p < 0.0001$.

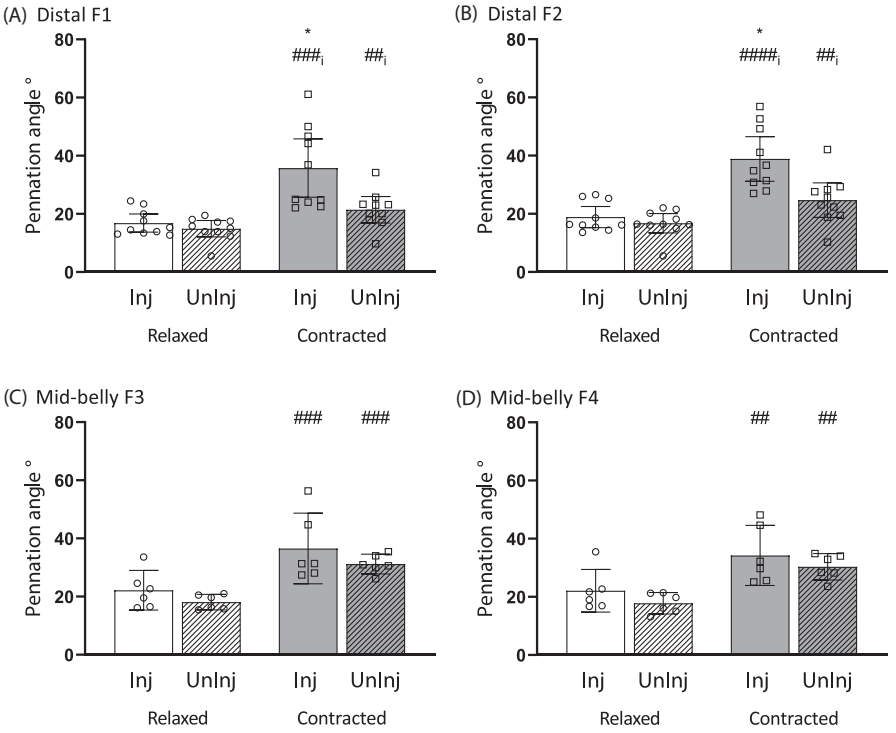

FIGURE 4 Pennation angle at the insertion of the injured (Inj) and uninjured (Uninj, striated bars) GM, in the relaxed (white) and at contracted (gray) state during unilateral heel rise. (A) Angle of the insertion of the most distal fascicle (F1). (B) Angle of the insertion of the distal fascicle (F2), $n = 10$. (C) Angle of the mid-belly fascicle F3 and (D) angle of insertion of the mid-belly fascicle F4; $n = 6$. White bars, relaxed state; gray bars, contracted state. *Significant difference from uninjured; #significant difference from relaxed. Main effects, unless marked with i, significant interaction between side and contraction state. Mean ± 95% CI. $^{\#}p < 0.05$, $^{\#\#}p < 0.01$, $^{\#\#\#}p < 0.001$, $^{\#\#\#\#}p < 0.0001$.

comparisons) (Figure 3F). In addition, at the central and medial positions there was also a main effect of side with higher pennation angle on the injured compared to the uninjured GM (5.6°, $p = 0.04$, CI = 0.3–10.8° and 5.5°, $p = 0.046$, CI = 0.1–10.9° for central and medial, respectively), (Figure 3D,E).

16000838, 0, Downloaded from https://onlinelibrary.wiley.com/doi/10.1111/sms.14472 by Ohio State University Ohio Sta, Wiley Online Library on [25/08/2023]. See the Terms and Conditions (https://onlinelibrary.wiley.com/terms-and-conditions) on Wiley Online Library for rules of use; OA articles are governed by the applicable Creative Commons License

Video recordings during the heel-rise showed that the pennation angle at the distal portion (both F1 and F2) displayed a significant interaction between the contraction state of the muscle and side (injured/uninjured). At the distal F1, there was an increase in pennation angle from the relaxed to peak contraction in the uninjured GM (6.6°, $p = 0.006$, CI 2.2°–10.9°), and also the injured GM (18.9°, $p = 0.0009$, CI 9.4°–28.4°). The increase in pennation angle was significantly greater in the injured compared to the uninjured side (12.4°, $p = 0.01$, CI 3.6°–21.1°), (Figure 4A). At F2, the pennation angle also increased on both the uninjured (7.9°, $p = 0.005$, CI 2.8°–13.0°) and the injured GM (20.0°, $p < 0.0001$, CI 12.8°–27.1°) from the relaxed to peak contraction (Figure 4B). The increase was again significantly greater in the injured compared to the uninjured side (12.1°, $p = 0.005$, CI 4.7°–19.5°) In addition to the quantifiable data, it was observed that the distal fascicles on the injured side rolled inward during contraction and had a curved appearance at maximal contraction (Figure 5B,D,F,H), in contrast to the taut fascicle shape on the uninjured side (Figure 5A,C,E,G). At the mid-belly of the GM, there was no interaction for the pennation angle, but a main effect of the contraction state showing an increase with contraction at F3 (13.7°, $p = 0.0002$, CI 10.2°–17.3°), (Figure 4C) and F4 (12.4°, $p = 0.002$, CI 7.0°–17.7°), (Figure 4D). Further, the curved appearance of the fascicles during contraction was not observed in the mid-belly portion of the GM.

3.3 | Fascicle length

There were no interactions for fascicle length measured on US still images. At the distal GM, medial position, there was a main effect of ankle angle with shorter fascicles at 110° compared to 90° (7.8 mm, $p = 0.003$, CI = 2.6–13.0 mm) and 80° (7.8 mm, $p = 0.003$, CI = 2.6–13.0 mm) (Figure 6B). The central and lateral positions did not display an effect of ankle angle (Figure 6A,C), but at the central position, there was a main effect of side (injured vs. uninjured) where the fascicle length was shorter on the injured compared to the uninjured GM (11.0 mm, $p = 0.004$, CI = 4.5 mm–17.6 mm) (Figure 6A). The fascicle length was not statistically different between the injured and uninjured GM on the medial and lateral position.

In the mid-belly, all three scan locations displayed a main effect of ankle angle, and no effect of side. For the central position, fascicles were shorter at 110° compared to 80° (9.6 mm, $p = 0.01$, CI = 2.2–16.9 mm) (Figure 6D). In the medial position fascicles were shorter at 110° compared to both 90° (5.8 mm, $p = 0.02$, CI = 1.0–10.7 mm) and 80° (10.0 mm, $p = 0.0001$, CI = 5.2–14.8 mm), (Figure 6E). At the lateral position fascicles were also shorter at 110° compared to both 90° (8.3 mm, $p = 0.004$, CI = 2.7–13.9 mm) and 80° (10.4 mm, $p = 0.0004$, CI = 4.8–16.0 mm), (Figure 6F).

Video analysis revealed no interactions between side and contraction state for any of the fascicles. A main effect of side was only observed for the distal fascicle F1, being shorter on the injured side compared to the uninjured

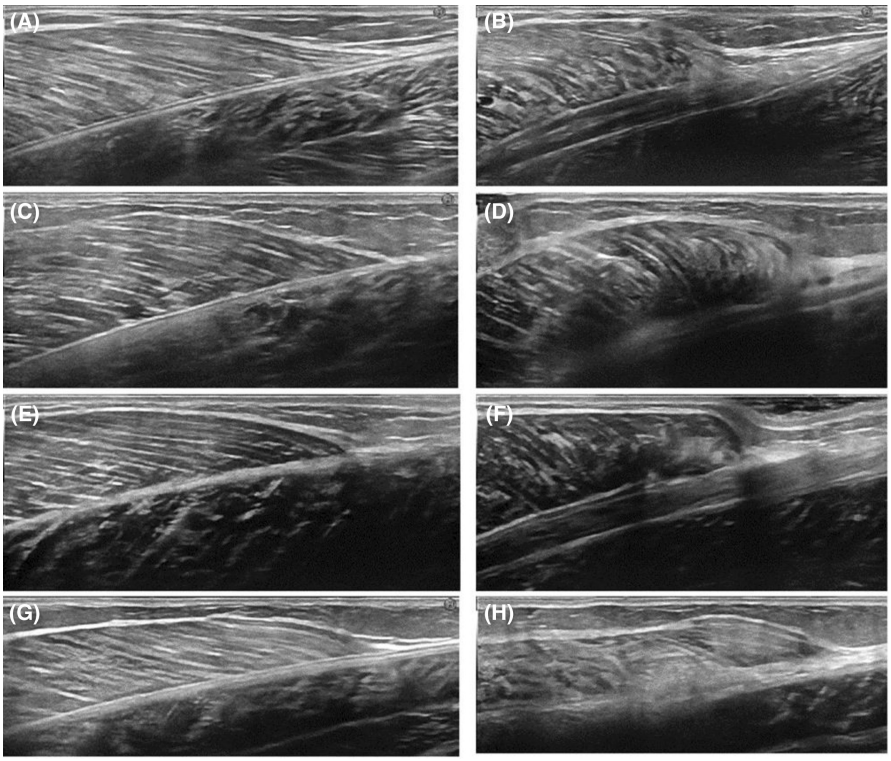

FIGURE 5 Frames of dynamic ultrasound recordings when the muscle was contracted (peak contraction during the heel rise at 6 ± 0.5 cm above the ground) obtained from four different participants. (A, C, E, G) Uninjured gastrocnemius and aponeurosis; (B, D, F, H) Injured gastrocnemius and aponeurosis.

16000838, 0, Downloaded from https://onlinelibrary.wiley.com/doi/10.1111/sms.14472 by Ohio State University Ohio Sta, Wiley Online Library on [25/08/2023]. See the Terms and Conditions (https://onlinelibrary.wiley.com/terms-and-conditions) on Wiley Online Library for rules of use; OA articles are governed by the applicable Creative Commons License

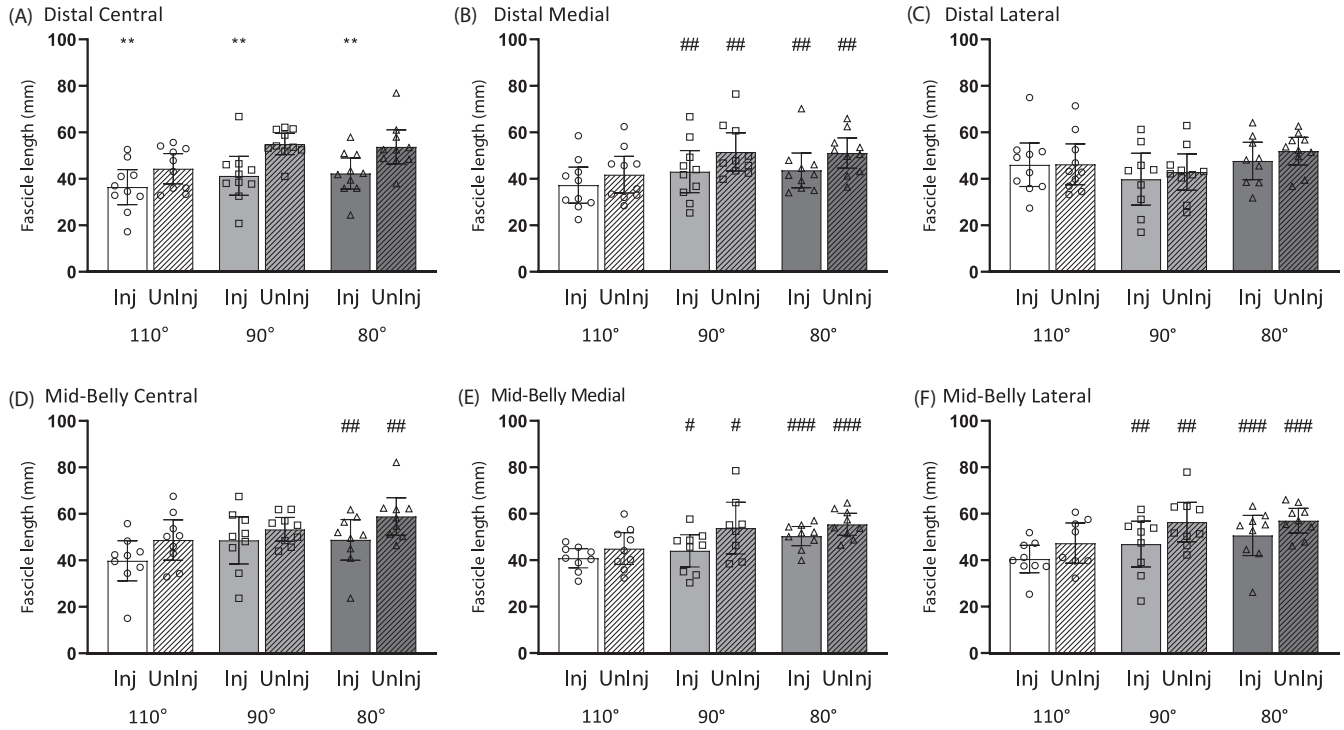

FIGURE 6 Fascicle length at the distal (A–C) and mid-belly (D–F) region of the GM at the three different ankle positions measured on ultrasound images. (A) and (D) central portion of the GM, (B) and (E) medial portion of the GM, and (C) and (F) lateral portion of the GM. White bars = ~110°, light gray bars = ~90° and dark gray bars = ~80°. $N = 10$. Inj, injured; UnInj, Uninjured (striated bars). *Significant difference from uninjured, #significant difference from 110°. Main effects reported. Mean ± 95% CI. $^{\#}p < 0.05$, $^{\#\#}p < 0.01$, $^{\#\#\#}p < 0.001$.

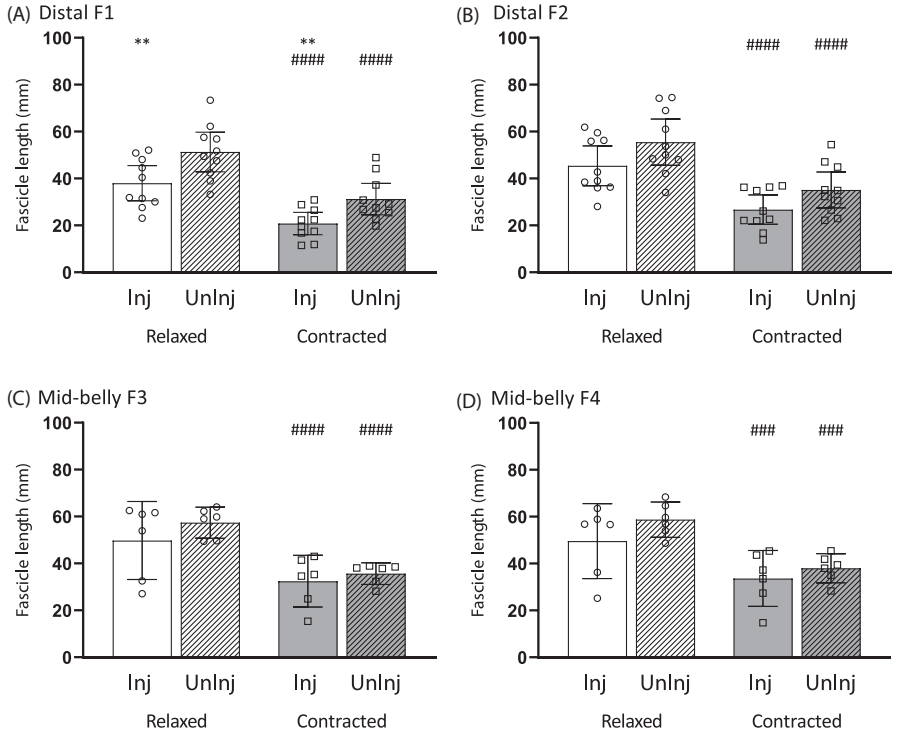

FIGURE 7 Fascicle length at the insertion of the injured (Inj) and uninjured (Uninj, striated bars) GM, in the relaxed (white) and at contracted (gray) state measured during unilateral heel rise. (A) Angle of the insertion of the most distal fascicle (F1). (B) Angle of the insertion of the distal fascicle (F2), $n = 10$. (C) Angle of the mid-belly fascicle F3 and (D) angle of insertion of the mid-belly fascicle F4; $n = 6$. White bars, relaxed state, gray bars, contracted state. *Significant difference from uninjured, #significant difference from relaxed. Main effects reported. Mean ± 95% CI $^{\#}p < 0.05$, $^{\#\#}p < 0.01$, $^{\#\#\#}p < 0.001$, $^{\#\#\#\#}p < 0.0001$.

(11.9 mm, $p = 0.009$, CI = 3.8–19.9 mm), (Figure 7A). All fascicles displayed a main effect of contraction state, shortening upon contraction (18.7 mm, $p < 0.0001$, CI = 15.0–22.3 mm; 19.5 mm, $p < 0.0001$, CI = 16.7–22.3 mm; 19.6 mm, $p < 0.0001$, CI = 15.6–23.5 mm, and 18.3 mm, $p = 0.0003$, CI = 13.2–23.5 mm for F1, F2, F3, and

16000838, 0, Downloaded from https://onlinelibrary.wiley.com/doi/10.1111/sms.14472 by Ohio State University Ohio Sta, Wiley Online Library on [25/08/2023]. See the Terms and Conditions (https://onlinelibrary.wiley.com/terms-and-conditions) on Wiley Online Library for rules of use; OA articles are governed by the applicable Creative Commons License

F4, respectively) (Figure 7A–D). In general, it should be noted that the curved appearance of the injured distal fascicles (Figure 5) complicated the accurate determination of fascicle length, and the present measures are based on linear extrapolation between fascicle insertion and origin, thereby neglecting curvilinearity of the fascicles.

3.4 | Aponeurosis thickness

For the aponeurosis thickness at the distal portion (D1 and D2), there was a significant interaction between the contraction state of the muscle and the side (injured/uninjured). The more proximal point (D3) showed no interaction, but a main effect of side. At the distal portion D1, there was an increase in aponeurosis thickness from the relaxed to peak contraction in the injured GM (1.4 mm, $p = 0.02$, CI 0.3–2.5 mm), but not in the uninjured GM. The increase in aponeurosis thickness was significantly greater in the injured compared to the uninjured side (1.3 mm, $p = 0.02$, CI 0.3–2.3 mm), (Figure 8A). It was the same at D2, where aponeurosis thickness also increased from the relaxed to peak contraction in the injured GM (1.6 mm, $p = 0.02$, CI = 0.3–2.9 mm), but not in the uninjured GM. Just as for D1, at D2, the aponeurosis thickness increased more in the injured compared to the uninjured (1.4 mm, $p = 0.02$, 0.2–2.5 mm), (Figure 8A,B). For aponeurosis thickness at D3, there was a main effect of side, meaning that there was a significant enlarged aponeurosis at the injured GM compared to the uninjured GM (5.9 mm, $p = 0.0003$, CI = 3.5–8.2 mm), (Figure 8C). At the mid-belly of the GM, no interactions were found nor any effects of contraction state, but there were main effects of side for all three sites measured. The injured aponeurosis was more enlarged at the injured, compared to the uninjured GM (3.3 mm, $p = 0.04$, CI = 0.3–6.3 mm; 3.5 mm, $p = 0.04$, CI = 0.3–6.6 mm, and 3.1 mm, $p = 0.04$, CI = 0.2–6.0 mm for M1, M2, and M3, respectively), (Figure 8D–F).

3.5 | Electromyography

During the heel rise exercise, there was a significant difference in the inter-muscle EMG activity. The normalized GM EMG during heel rise did not differ between the injured and uninjured calf (Figure 9A), but the normalized soleus (SOL) EMG activity during a heel rise task was significantly greater in the injured than the healthy calf ($p = 0.02$), (Figure 9B). Consequently, the ratio of SOL to GM EMG activity was significantly greater in the injured

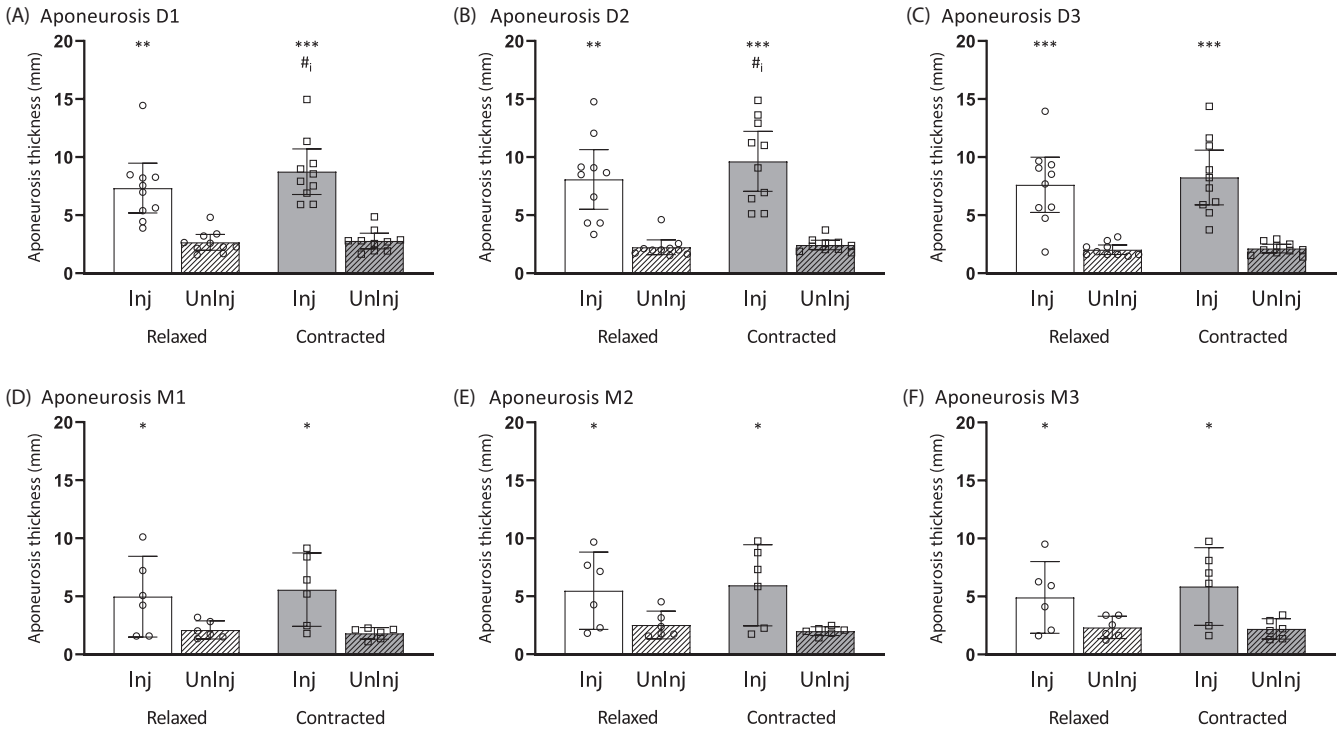

FIGURE 8 Aponeurosis thickness at three different sites measured at the distal GM (A–C) ($n = 10$) and the mid-belly GM (D–F) ($n = 6$) measured during unilateral heel rise. (A) and (D) Thickness at the most distal fascicle (D1/M1). (B) and (E) Greatest aponeurosis thickness (D2/M2). (C) and (F). Thickness at the proximal fascicle (D3/M3). Inj, injured, UnInj, Uninjured (striated bars). White bars, relaxed state, gray bars, contracted state. *Significant difference from uninjured, #significant difference from relaxed. Main effects, unless marked with i, significant interaction between side and contraction state. Mean ± 95% CI *$p < 0.05$, **$p < 0.01$, ***$p < 0.001$.

16000838, 0, Downloaded from https://onlinelibrary.wiley.com/doi/10.1111/sms.14472 by Ohio State University Ohio Sta, Wiley Online Library on [25/08/2023]. See the Terms and Conditions (https://onlinelibrary.wiley.com/terms-and-conditions) on Wiley Online Library for rules of use; OA articles are governed by the applicable Creative Commons License

than the uninjured calf ($p = 0.04$, (Figure 9C). Note, that for some participants the EMG activity was greater during heel rise than during the MVC with extended knee, which was unexpected, but as normalization was performed identically for both the injured and uninjured leg, we believe that the comparison of the two is still valid. The strength output during the MVC was not different between the injured and the uninjured calf.

4 | DISCUSSION

The data of the present study suggest that a human muscle strain injury causes long-term, and possibly permanent, functional and structural changes. The pennation angle in the injured distal GM increases significantly during contraction, more than in the uninjured GM and the most distal fascicles are shorter. There is a pronounced thickening of the aponeurosis, which is even more enlarged during muscle contraction. There is an altered neuromuscular activation pattern of the previously injured calf muscles during a heel-rise movement. In fact, the behavior of the most distal fascicles of the injured GM during dynamic US recordings indicate that the site of the previous injury does not actively produce contractile force due to the pronounced curving of the fascicles observed during the heel rise movement, indicating a lack of fascicle shortening. Finally, the significantly thickened aponeurosis is a clear indication of a substantial involvement of the connective tissue (i.e., the aponeurosis) during injury and thereby also in the following repair process.

The analysis of the dynamic US recordings shows that the fascicles in the distal part behave differently compared to fascicles in the healthy GM, and we hypothesize that these observations represent inactive, noncontracting muscle fibers. We further hypothesize that the fascicles are pulled by the aponeurosis instead of the fascicles pulling on the aponeurosis as they contract. The steep pennation angle at contraction in the injured distal GM provides quantifiable data to support this theory. Further the pronounced curvilinear shape of the fascicles at the insertion into the deep aponeurosis toward the end of the contractions at the distal GM serves as more qualitative observations (see Figure 5). On a technical note, it means that the pennation angle is even higher, at least directly at the insertion where the curvature is most pronounced. The automated macro used in this study to calculate pennation angle in the US video recordings assumes a linear shape of the fascicles and the assumption of linearity also means that the fascicle length is underestimated relative to the actual curved path. Another observation of the distal injured GM is the presence of areas where fascicles are not easily identifiable at the most contracted state (Figure 4), suggesting that these areas are altered in their structure and the structure around the fascicles. One potential explanation could be the extensive fat infiltration, which we reported in a previous study on chronic muscle strain injuries.[10]

Despite our inability to quantify the microscopic ultrastructure of the distal muscle fascicles and the aponeurosis in the injured GM in this study, which would have required biopsies from the site, it is quite clear that muscle fascicles behave differently. Although we lack displacement measurements of the aponeurosis during movement, the significant enlargement of the aponeurosis at any site measured, which becomes even more pronounced at contraction does suggest that the material of the aponeurosis, its organization and thereby likely also the material properties are different compared to the uninjured calf. Along the line of this hypothesis, we propose that the firm connection between the two structures has not been properly restored in chronic strain injuries of the GM. Previous results from our group support this assertion.[10] Whether this is due to a weakening of the aponeurosis material properties, or the inability of the distal GM to contract due to lesser motor unit recruitment, cannot be answered based on these data. Significant loss of muscle mass is reported post muscle strain injuries, in both hamstrings and calf muscles.[8,9] The mechanism for muscle atrophy is likely multifactorial following a traumatic injury and may include reduced motor unit recruitment to some degree in addition to the immobilization associated effects. We speculate that a lack of muscle contraction could hinder the strengthening of the aponeurosis and the muscle-connective tissue interface and further hypothesize that this lack of aponeurosis and muscle-aponeurosis interface strengthening is a key contributor to the high risk of reinjury associated with muscle strain injuries.

Although the current study does not allow analysis of the material properties per se, we do observe a different behavior of the aponeurosis on the injured compared to the healthy side. First, compared to the unaffected calf the aponeurosis displays significant enlargement, which extends into the mid-belly portion of the injured GM. Second, the slight increase in aponeurosis thickness in the uninjured GM distally, and the slight decrease in aponeurosis thickness in the uninjured GM mid-belly as a result of the muscle contraction (Figure S2) is not seen in the injured calf. Instead, the aponeurosis increases significantly in thickness at both sites as the injured muscle contracts (Figure S2). We cannot directly compare the two sites with each other as the videos of the mid-belly were only recorded in six participants, but the pattern observed is still noteworthy. Finni et al.[15] reported a nonuniform strain along the length of the healthy aponeurosis where the SOL aponeurosis of the mid-belly site lengthened,

16000838, 0, Downloaded from https://onlinelibrary.wiley.com/doi/10.1111/sms.14472 by Ohio State University Ohio Sta, Wiley Online Library on [25/08/2023]. See the Terms and Conditions (https://onlinelibrary.wiley.com/terms-and-conditions) on Wiley Online Library for rules of use; OA articles are governed by the applicable Creative Commons License

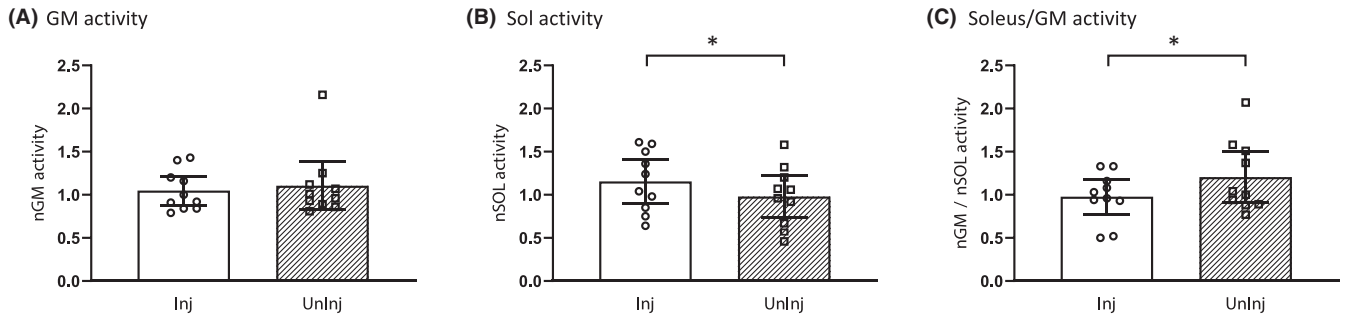

FIGURE 9 Surface EMG recordings of the GM and the soleus (SOL) during a heel rise movement normalized to the EMG during individual MVC in the extended knee position. (A) GM activation pattern normalized to the MVC at the extended knee position, (B) SOL activation pattern normalized to the MVC at the extended knee position, (C) Ratio of GM to SOL activation, both normalized to the MVC at the extended knee position. $N = 10$, mean ± SD. Inj, injured; UnInj, uninjured; nSOL, normalized SOL activity; nGM, normalized GM activity, $*p < 0.05$.

whereas the distal aponeurosis shortened. Our data obtained in the healthy GM aponeurosis agree well with the observations made by Finni et al[15] as a reduction in the mid-belly aponeurosis dimensions along one axis (thinning), suggests an increase along another axis (lengthening), and vice-versa at the distal end. Heterogeneous strain of the aponeurosis has also been described in cat GM muscle,[28] and Azizi and Roberts described the simultaneous increase in length and width of GM aponeurosis of wild turkeys during contractions.[12]

On a functional level, the EMG data obtained during a unilateral heel rise showed a higher myoelectrical activity of the soleus relative to the injured GM activity compared to the healthy calf. This difference in the activation pattern of the two calf muscles suggests a distinct strategy of the injured calf to be able to perform the movement task, where the SOL contributes more in the injured compared to the healthy calf. These data are in line with previous reports following hamstring muscle strains, where the authors documented a lower level of EMG activity of the previously injured BFlh compared to the uninjured BFlh during eccentric muscle actions.[23,29] Also, a recent review paper on myoelectrical activity in previously injured hamstrings reported a moderate to limited evidence that the activation pattern of the hamstrings muscles appears different in comparison to the healthy hamstrings, especially during eccentric muscle contractions.[25] Our EMG data does not discern between the concentric and the eccentric phase and it might be that there might have been a larger difference in particularly the eccentric component of the heel rise movement. Pain as a result of strain injury has been discussed as a factor in the maladaptation of the neural function measurable as a decrease in myoelectrical activity.[30] However, chronic pain has not been reported in any of the individuals participating in the present study and it appears unlikely that pain from the acute trauma several months to years back still has an impact on the muscle activation pattern. Instead, the present EMG data with a higher soleus activity might be interpreted as a protective mechanism, or a compensatory mechanism for a potential reduction in motor unit recruitment of the injured distal GM. This remains, however, speculative, and as the current study did not test the myoelectrical activation pattern during other movements than the controlled slow heel rise, we can only speculate that the inter-muscle activation pattern during explosive movements is also different in a previously injured compared to an uninjured calf. It is also important to note that we did not use high-density EMG methods to discern the muscle activation pattern in different areas of a muscle, but EMG with the electrodes placed at mid-belly GM, which is not the site of the injury and not the side of the most pronounced changes in fascicle length and pennation angle.

Repeated eccentric muscle contractions of the hamstrings, such as the Nordic Hamstrings exercise, have convincingly been shown to be preventive of first time hamstring strain injuries, and also of recurrent injuries.[17] The preventive role of eccentric exercises has been linked to the increase in fascicle length[31] and conversely, a short fascicle length has been associated with an increased risk of sustaining a hamstring strain injury.[32] Whether the same pattern is true for the GM has not been investigated but it is reasonable to assume that a short fascicle length in the GM might also increase the risk of sustaining a calf injury. The present study measured significantly shortened fascicles at rest and at peak contraction at the most distal part and while we have not obtained sarcomere data in this study, our previous report based on biopsy material from chronic strain injured muscle showed disordered, hypercontracted sarcomeres, and loss of sarcomere structure.[10] Together, these data suggest that the architecture and function of the injured GM is permanently changed. So far, it is unknown whether targeted eccentric training

16000838, 0, Downloaded from https://onlinelibrary.wiley.com/doi/10.1111/sms.14472 by Ohio State University Ohio Sta, Wiley Online Library on [25/08/2023]. See the Terms and Conditions (https://onlinelibrary.wiley.com/terms-and-conditions) on Wiley Online Library for rules of use; OA articles are governed by the applicable Creative Commons License

of the injured GM would increase fascicle length, also in the very distal part.

This study is not without limitations. The assumption of linearity when calculating fascicle length is a clear limitation to this study, especially for the measurement of fascicle length and pennation angle of the injured GM as the fascicles followed a pronounced curvilinear path. Due to the structural disruption frequently observed in the injured muscle, it was, however, not possible to accurately trace the fibers to quantify their actual curved path. During dynamic movements, it can be difficult to maintain perfect alignment with the muscle fascicles as they move under the probe, especially in the distal region; however, we feel confident that our recordings are as close to alignment as is possible with a 2D technique during dynamic contraction. Further, the US recordings were not designed to measure the mechanical properties of the aponeurosis, which would have given further insight into the aponeurosis performance following a strain injury. Additionally, all measurements are performed on two-dimensional US images and videos. This report has not included a healthy control group to control for side-to-side differences. Finally, we have chosen to perform a heel-rise test as a dynamic movement to resemble movements during normal, daily physical activity. We tried to control the movement as tightly as possible so that instructions were followed by the participants. However, a more controlled, isometric contraction would have been a more standardized test situation. In line with this, the heel rise was not separated into the concentric and eccentric compartment, which would have given more information. Further, high-density EMG would have given more detailed information about the muscle activation pattern in different areas of the muscles.

5 | CONCLUSION

We conclude that this study provides data indicating that a part of the injured distal GM is behaving differently compared to the healthy side in that the muscle fascicles display a steep increase in pennation angle during contraction and further appear to be pulled and thereby bending inward. We hypothesize that this behavior visualizes not actively contracting fascicles following a strain injury, and further analyses have to confirm this assumption. We also report that the aponeurosis following the injury is altered in both structure and function. An altered neuromuscular activation pattern of calf muscles in chronic strain injuries is potentially supported by the EMG data. As the majority of participants sustained their injury years before these measurements, these changes of the muscle and the muscle-aponeurosis interface are likely permanent.

5.1 | Perspective

The present data suggest that part of the previously injured GM does behave very different and might not actively contract. If fascicles at the distal GM do not contract with voluntary muscle activation after a strain injury, the muscle as well as the associated connective tissue (aponeurosis) is not subjected to essential mechanical tension. These findings are relevant particularly as loss of muscle mass and development of fatty infiltration occur after muscle strain injuries, and both muscle atrophy and fatty infiltrations might be directly linked to the observations presented in this report. Our observations might also explain the high risk of recurrence after strain injuries and motivate for new thinking of rehabilitative measures after a muscle strain injury to reduce injury sequela.

ACKNOWLEDGMENTS

The authors thank all the participants for their participation in this study. This study was funded by the Danish Ministry of Culture (FPK.2019-0049) and by the Bispebjerg-Frederiksberg Research grant 2019.

CONFLICT OF INTEREST STATEMENT

The authors declare no conflict of interest.

DATA AVAILABILITY STATEMENT

The data that support the findings of this study are available on request from the corresponding author. The data are not publicly available due to privacy or ethical restrictions.

ORCID

Rene B. Svensson https://orcid.org/0000-0002-1607-5379
Kenneth H. Mertz https://orcid.org/0000-0003-0320-0836
S. Peter Magnusson https://orcid.org/0000-0002-4308-5484
Michael Kjaer https://orcid.org/0000-0002-4582-8755
Monika L. Bayer https://orcid.org/0000-0002-6720-6543

REFERENCES

1. Hägglund M, Waldén M, Ekstrand J. Injury recurrence is lower at the highest professional football level than at national and amateur levels: does sports medicine and sports physiotherapy deliver? *Br J Sports Med*. 2016;50:751-758.
2. Ekstrand J, Waldén M, Hägglund M. Hamstring injuries have increased by 4% annually in men's professional football, since 2001: a 13-year longitudinal analysis of the UEFA elite Club injury study. *Br J Sports Med*. 2016;50:731-737.
3. Green B, Pizzari T. Calf muscle strain injuries in sport: a systematic review of risk factors for injury. *Br J Sports Med*. 2017;51:1189-1194.

16000838, 0, Downloaded from https://onlinelibrary.wiley.com/doi/10.1111/sms.14472 by Ohio State University Ohio Sta, Wiley Online Library on [25/08/2023]. See the Terms and Conditions (https://onlinelibrary.wiley.com/terms-and-conditions) on Wiley Online Library for rules of use; OA articles are governed by the applicable Creative Commons License

4. Hägglund M, Waldén M, Ekstrand J. Risk factors for lower extremity muscle injury in professional soccer: the UEFA injury study. *Am J Sports Med*. 2013;41:327-335.
5. Tidball JG, Salem G, Zernicke R. Site and mechanical conditions for failure of skeletal muscle in experimental strain injuries. *J Appl Physiol*. 1993;74:1280-1286.
6. Garrett WE. Muscle strain injuries. *Am J Sport Med*. 1996;24:S2-S8.
7. Askling CM, Tengvar M, Saartok T, Thorstensson A. Acute first-time hamstring strains during high-speed running: a longitudinal study including clinical and magnetic resonance imaging findings. *Am J Sport Med*. 2007;35:197-206.
8. Silder A, Heiderscheit BC, Thelen DG, Enright T, Tuite MJ. MR observations of long-term musculotendon remodeling following a hamstring strain injury. *Skeletal Radiol*. 2008;37:1101-1109.
9. Bayer ML, Hoegberget-Kalisz M, Jensen MH, et al. Role of tissue perfusion, muscle strength recovery and pain in rehabilitation after acute muscle strain injury: a randomized controlled trial comparing early and delayed rehabilitation. *Scand J Med Sci Sports*. 2018;28:2579-2591.
10. Bayer ML, Hoegberget-Kalisz M, Svensson RB, et al. Chronic sequelae after muscle strain injuries: influence of heavy resistance training on functional and structural characteristics in a randomized controlled trial. *Am J Sports Med*. 2021;49:2783-2794.
11. Arellano CJ, Gidmark NJ, Konow N, Azizi E, Roberts TJ. Determinants of aponeurosis shape change during muscle contraction. *J Biomech*. 2016;49:1812-1817.
12. Azizi E, Roberts TJ. Biaxial strain and variable stiffness in aponeuroses. *J Physiol*. 2009;587:4309-4318.
13. Magnusson SP, Hansen P, Aagaard P, et al. Differential strain patterns of the human gastrocnemius aponeurosis and free tendon, in vivo. *Acta Physiol Scand*. 2003;177:185-195.
14. Bojsen-Møller J, Magnusson SP. Mechanical properties, physiological behavior, and function of aponeurosis and tendon. *J Appl Physiol*. 2019;126:1800-1807.
15. Finni T, Hodgson JA, Lai AM, Edgerton VR, Sinha S. Nonuniform strain of human soleus aponeurosis-tendon complex during submaximal voluntary contractions in vivo. *J Appl Physiol*. 2003;95:829-837.
16. Timmins RG, Shield AJ, Williams MD, Lorenzen C, Opar DA. Biceps Femoris long head architecture. *Med Sci Sport Exerc*. 2015;47:905-913.
17. Petersen J, Thorborg K, Nielsen MB, Budtz-Jørgensen E, Hölmich P. Preventive effect of eccentric training on acute hamstring injuries in men's soccer: a cluster-randomized controlled trial. *Am J Sports Med*. 2011;39:2296-2303.
18. van der Horst N, Smits DW, Petersen J, Goedhart EA, FJG B. The preventive effect of the Nordic hamstring exercise on hamstring injuries in amateur soccer players: a randomized controlled trial. *Am J Sports Med*. 2015;43:1-8.
19. Marušič J, Vatovec R, Marković G, Šarabon N. Effects of eccentric training at long-muscle length on architectural and functional characteristics of the hamstrings. *Scand J Med Sci Sports*. 2020;30:2130-2142.
20. Whiteley R, Hickey JT, Vermeulen R, et al. Biceps Femoris fascicle lengths increase after hamstring injury rehabilitation to a greater extent in the injured leg. *Transl Sport Med*. 2022;2022:1-8.
21. Ekstrand J, Hägglund M, Waldén M. Epidemiology of muscle injuries in professional football (soccer). *Am J Sports Med*. 2011;39:1226-1232.
22. Franchi MV, Fitze DP, Raiteri BJ, Hahn D, Spörri J. Ultrasound-derived biceps Femoris long head fascicle length: extrapolation pitfalls. *Med Sci Sports Exerc*. 2020;52:233-243.
23. Opar DA, Williams MD, Timmins RG, Dear NM, Shield AJ. Knee flexor strength and bicep femoris electromyographical activity is lower in previously strained hamstrings. *J Electromyogr Kinesiol*. 2013;23:696-703.
24. Opar DA, Williams MD, Timmins RG, Dear NM, Shield AJ. Rate of torque and electromyographic development during anticipated eccentric contraction is lower in previously strained hamstrings. *Am J Sports Med*. 2013;41:116-125.
25. Presland JD, Timmins RG, Maniar N, et al. Muscle activity and activation in previously strain-injured lower limbs: a systematic review. *Sports Med*. 2021;51:2311-2327.
26. Bayer MLML, Magnusson SPP, Kjaer M. Early versus delayed rehabilitation after acute muscle injury. *N Engl J Med*. 2017;377:1300-1301.
27. Silbernagel KG, Nilsson-Helander K, Thomeé R, Eriksson BI, Karlsson J. A new measurement of heel-rise endurance with the ability to detect functional deficits in patients with Achilles tendon rupture. *Knee Surg Sports Traumatol Arthrosc*. 2010;18:258-264.
28. Zuurbier CJ, Everard AJ, van der Wees P, Huijing PA. Length-force characteristics of the aponeurosis in the passive and active muscle condition and in the isolated condition. *J Biomech*. 1994;27:445-453.
29. Buhmann R, Trajano GS, Kerr G, Shield A. Voluntary activation and reflex responses after hamstring strain injury. *Med Sci Sports Exerc*. 2020;52:1862-1869.
30. Opar DA, Williams MD, Shield AJ. Hamstring strain injuries: factors that lead to injury and re-injury. *Sports Med*. 2012;42:209-226.
31. Guex K, Degache F, Morisod C, Sailly M, Millet GP. Hamstring architectural and functional adaptations following long vs. *Short Muscle Length Eccentric Training Front Physiol*. 2016;7:340.
32. Timmins RG, Bourne MN, Shield AJ, Williams MD, Lorenzen C, Opar DA. Short biceps femoris fascicles and eccentric knee flexor weakness increase the risk of hamstring injury in elite football (soccer): a prospective cohort study. *Br J Sports Med*. 2016;50:1524-1535.

SUPPORTING INFORMATION

Additional supporting information can be found online in the Supporting Information section at the end of this article.

How to cite this article: B. Nielsen L, B. Svensson R, U. Fredskild N, et al. Chronic changes in muscle architecture and aponeurosis structure following calf muscle strain injuries. *Scand J Med Sci Sports*. 2023;00:1-13. doi:10.1111/sms.14472

16000838, 0, Downloaded from https://onlinelibrary.wiley.com/doi/10.1111/sms.14472 by Ohio State University Ohio Sta, Wiley Online Library on [25/08/2023]. See the Terms and Conditions (https://onlinelibrary.wiley.com/terms-and-conditions) on Wiley Online Library for rules of use; OA articles are governed by the applicable Creative Commons License